



Extralaryngeal Division Of The Inferior Laryngeal Nerve (ILN) A Common Risk In Thyroid Surgery

Mame Sanou Diouf^{1*}, Cire Ndiaye², Birame Loum³, Moustapha Ndiaye⁴, Amadou Thiam⁵

¹ENT department, Idrissa Pouye general hospital1

²ENT department, Fann national university hospital center2

³ENT department Albert Royer children's hospital3

⁴ENT department, Idrissa Pouye general hospital1

⁵ENT department, Idrissa Pouye general hospital1

*Corresponding Author: Mame Sanou Diouf, ENT department, Idrissa Pouye general hospital1.

Received: 📅 November 29, 2023

Accepted: December 23, 2023

Published: 📅 January 04, 2024

Conflict of Interest

The authors declare no conflict of interest.

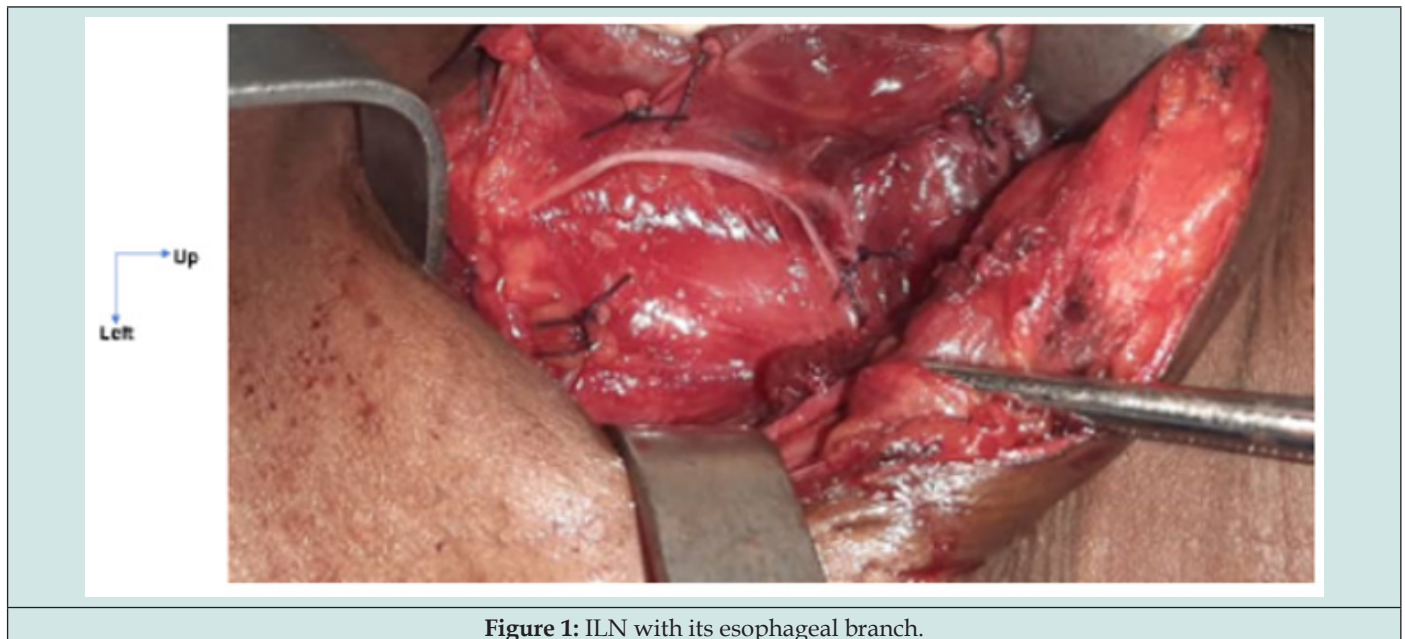


Figure 1: ILN with its esophageal branch.

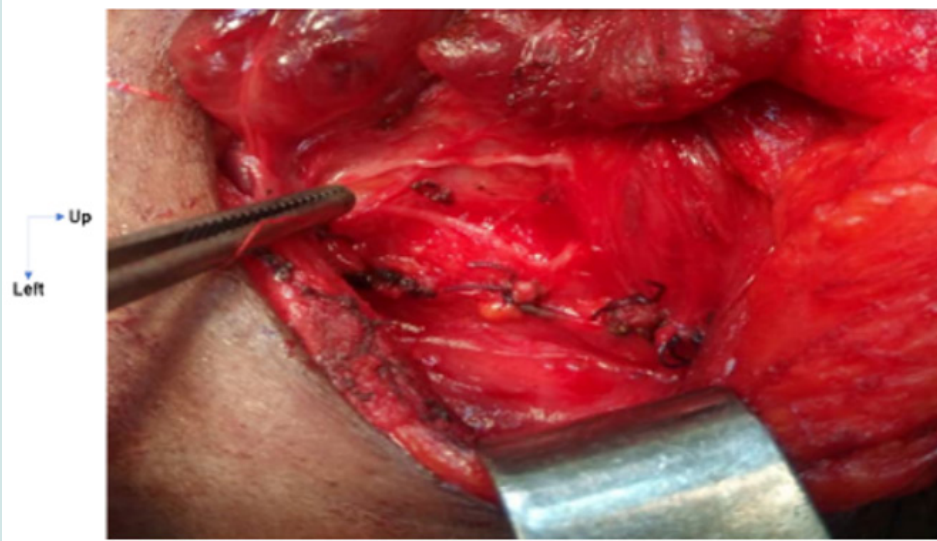


Figure 2: Bifid ILN.

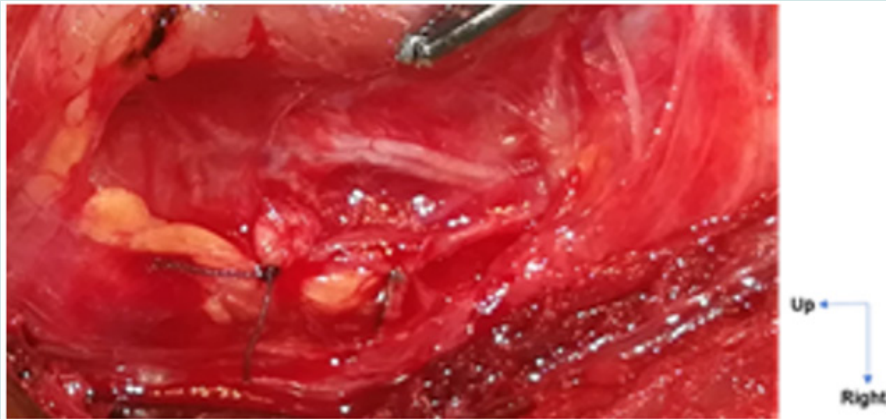


Figure 3 : Bifid ILN.

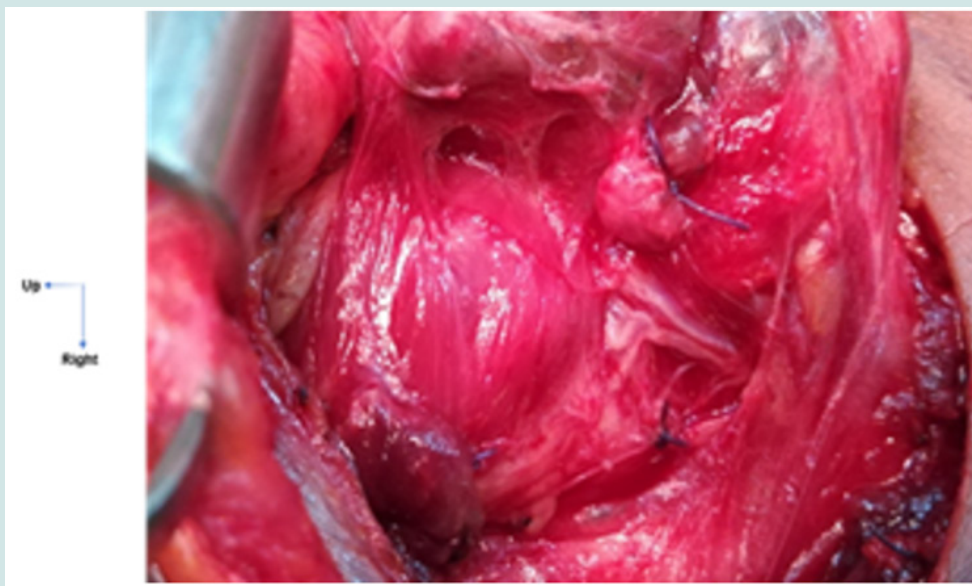

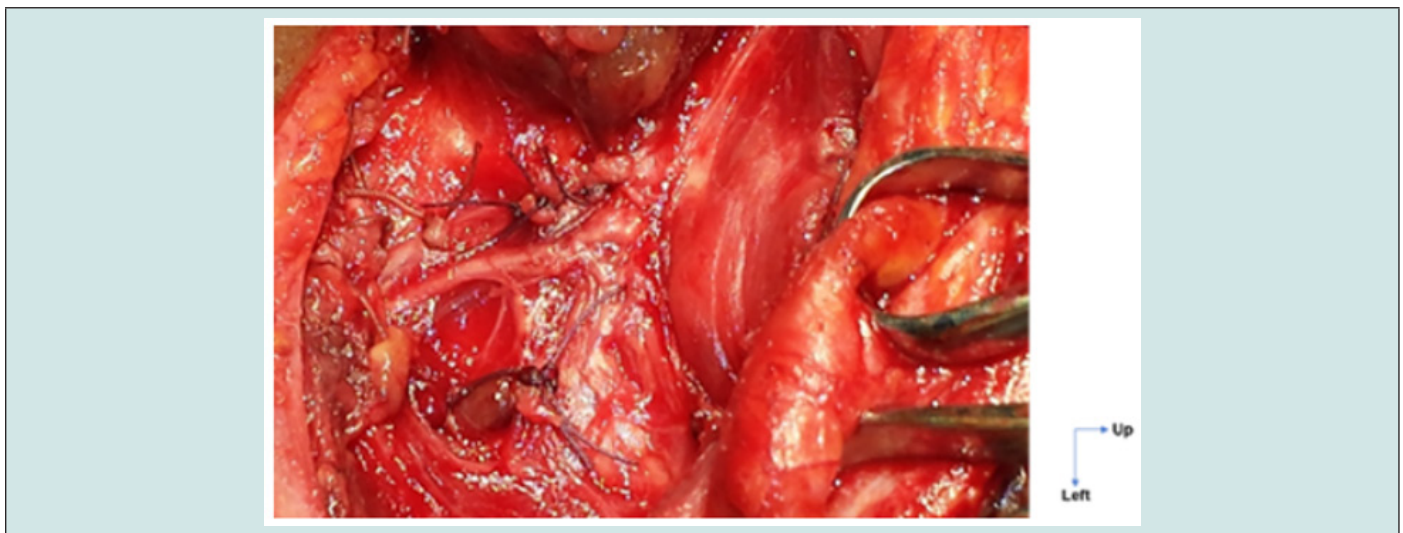
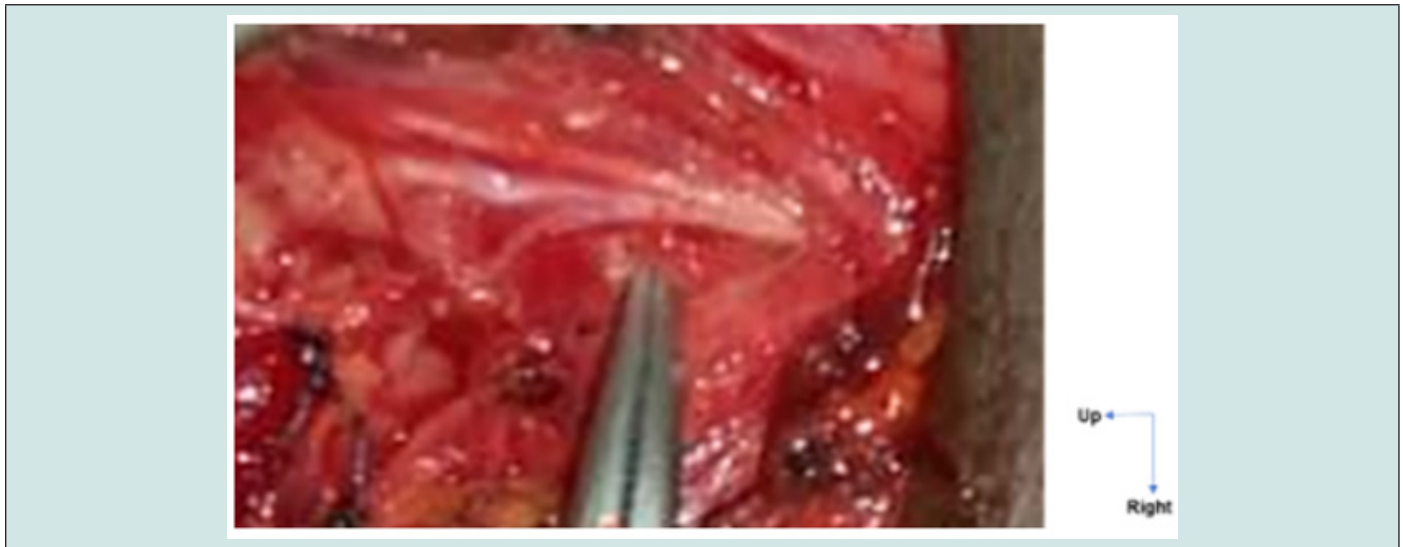
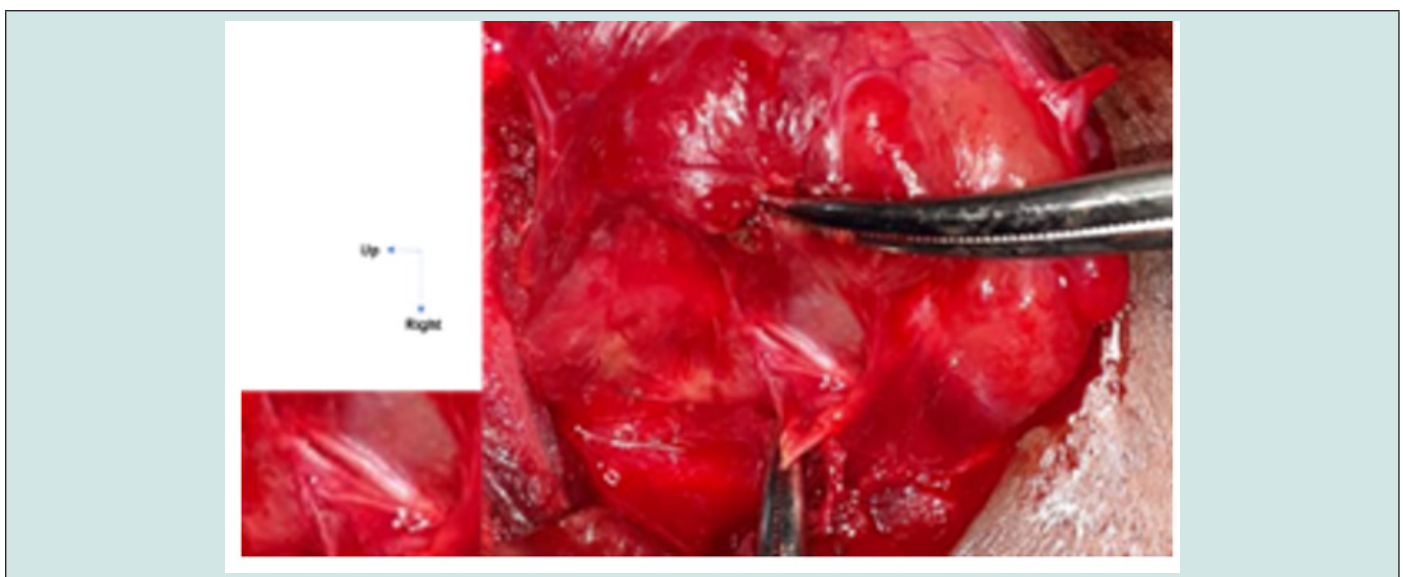
Figure 4: Trifurcated ILN with tracheal branches.



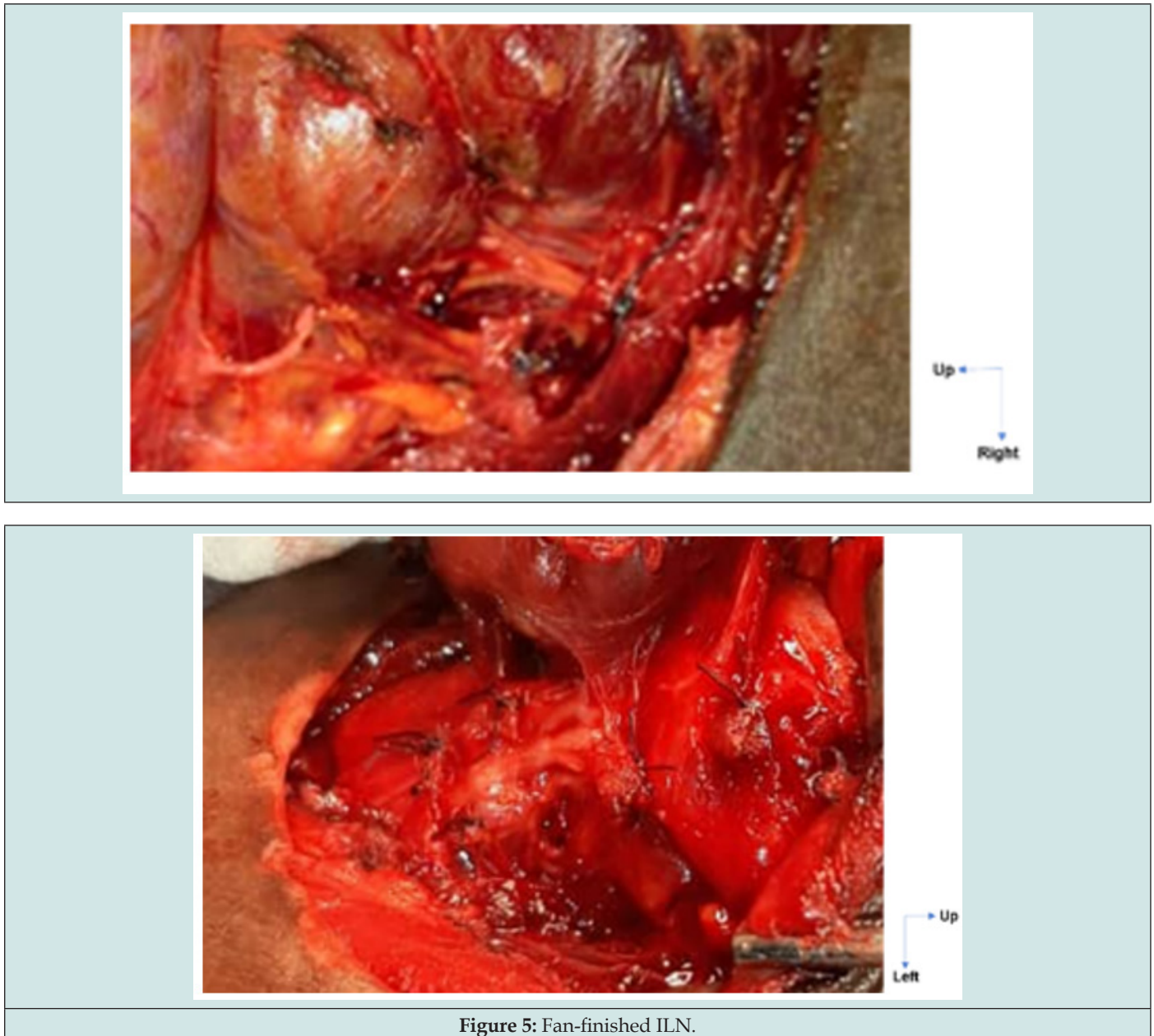




Figure 5: Fan-finished ILN.

 This work is licensed under Creative Commons Attribution 4.0 License

To Submit Your Article Click Here: [Submit Article](#)

DOI: [10.32474/SJO.2024.10.000338](https://doi.org/10.32474/SJO.2024.10.000338)



Scholarly Journal of Otolaryngology Assets of Publishing with us

- Global archiving of articles
- Immediate, unrestricted online access
- Rigorous Peer Review Process
- Authors Retain Copyrights
- Unique DOI for all articles